

# Change in Liver Size and Fat Content after Treatment with Optifast® Very Low Calorie Diet

Mark C. Lewis, BMBS<sup>1</sup>; Madeleine L. Phillips, BSc(Hons)<sup>2</sup>; John P. Slavotinek, BSc, FRANZCR<sup>3</sup>; Lilian Kow, PhD, FRACS<sup>1</sup>; Campbell H. Thompson, MD, DPhil, FRACP<sup>2</sup>; Jim Touli, PhD, FRACS<sup>1</sup>

Departments of <sup>1</sup>General and Digestive Surgery, <sup>2</sup>Medicine and <sup>3</sup>Medical Imaging, Flinders Medical Centre, Flinders University of South Australia, Bedford Park, South Australia, Australia

**Background:** Laparoscopic adjustable gastric banding (LAGB) requires surgical access to the gastroesophageal junction, which may be compromised by the enlarged, fatty liver that is frequently encountered in the obese. Liver size appears reduced and surgical access improved following preoperative weight loss with Optifast® Very Low Calorie Diet (VLCD). The aim of this study was to assess the effects of 6 weeks Optifast® VLCD on liver volume and fat content.

**Methods:** 18 morbidly obese subjects underwent magnetic resonance imaging and spectroscopy to measure liver size and fat content before and after intensive treatment with Optifast® VLCD for 6 weeks.

**Results:** All subjects completing 6 weeks Optifast® VLCD lost weight. Body weight and BMI (median [interquartile range]) reduced from 119.7 [111.9-131.3] kg and 44 [40-51] kg/m<sup>2</sup> respectively, to 110.6 [98.0-124.5] kg and 40 [36-47] kg/m<sup>2</sup>,  $P < 0.001$ . Median excess weight loss (EWL) was 15.1 [9.6-21.1]%. Baseline liver volume and fat content were related ( $r = 0.633$ ,  $P = 0.005$ ). After 6 weeks Optifast® VLCD, there was a 14.7% reduction in mean liver volume ( $P < 0.001$ ) and a 43% reduction in mean liver fat ( $P = 0.016$ ). The change in liver volume was predicted by the change in the liver fat ( $r = 0.610$ ,  $P = 0.012$ ).

**Conclusion:** This study has demonstrated that a 6-week diet with Optifast® VLCD results in significant related reductions in liver size and liver fat content. This suggests that the reduction in liver volume is due to loss of fat. The reduction in liver fat and volume likely accounts for the perceived improved operability in patients undergoing LAGB.

**Key words:** Liver volume, hepatic steatosis, very low calorie diet, morbid obesity, laparoscopic gastric banding

## Introduction

Obesity is the most significant risk factor for the development of non-alcoholic fatty liver disease (NAFLD),<sup>1</sup> a term that encompasses a spectrum of liver pathology ranging from fatty liver alone (hepatic steatosis) to concomitant hepatic inflammation (non-alcoholic steatohepatitis or NASH). Although it is a relatively benign condition, hepatic steatosis increases risk of developing NASH which may then progress to more advanced stages of liver disease such as fibrosis and cirrhosis.<sup>2-4</sup>

NAFLD is estimated to occur in 30 to 100% of obese adults<sup>1</sup> and is associated with hepatic enlargement (hepatomegaly),<sup>5</sup> elevated serum aminotransferase levels<sup>5</sup> and insulin resistance.<sup>2,6</sup> The reversibility of hepatic steatosis following weight loss is evident from evaluation of computed tomography<sup>7</sup> and magnetic resonance imaging<sup>8</sup> scans before and after diet therapy, as well as from paired liver biopsies following very low calorie diet,<sup>9</sup> vertical banded gastroplasty,<sup>10</sup> laparoscopic adjustable gastric banding<sup>11</sup> and Roux-en-Y gastric bypass.<sup>12</sup> Reductions in liver size measured by imaging techniques following weight loss have been less frequently reported.<sup>13,14</sup>

Bariatric operations are more frequently being performed to address the rising global trend in morbid

Reprint requests to: M. L. Phillips, Department of General Medicine, Flinders Medical Centre, Bedford Park 5042, South Australia, Australia. Fax: 61-8-8204 6255; e-mail: Madeleine.phillips@fmc.sa.gov.au

obesity.<sup>15</sup> Laparoscopic adjustable gastric banding (LAGB) is one of the most widely performed of these techniques in Australia and around the world.<sup>15</sup>

There is anecdotal evidence that the laparoscopic procedure is made technically difficult by the presence of an enlarged liver. Furthermore, the procedure is relatively uncomplicated and quicker<sup>16</sup> following preoperative weight loss. Pre-operative adherence to a very low calorie diet (VLCD), defined as a total daily energy intake of between 400 and 800 kcal, reduces body weight and liver size and potentially improves surgical operability in the obese patient.<sup>14</sup> To date, the association between hepatomegaly and hepatic steatosis in obesity has been assumed.<sup>7,14</sup> There is inadequate evidence that the reduction in liver size following weight loss is attributable to the improvement or resolution of hepatic steatosis.

The aims of this study therefore were twofold: 1) to assess the effects of a 6-week course of Optifast® VLCD on liver size and fat content using magnetic resonance imaging (MRI) and proton magnetic resonance (<sup>1</sup>H-NMR) spectroscopy in a cohort of obese subjects awaiting bariatric surgery; and 2) to relate both the baseline and post-intervention changes in liver size and liver fat content.

## Materials and Methods

Patients on the waiting list for LAGB surgery at Flinders Medical Centre were contacted and offered enrollment in this study prior to their surgery. Exclusion criteria were weight >150 kg (maximum weight rating for the MRI machine), cirrhosis or active hepatitis, alcohol intake >20 g/day, pregnancy and lactation, recent stroke or myocardial infarction, type 1 diabetes mellitus with ketosis, porphyria and corticosteroid use (>20 mg/day for ≥3 months).

Patients unable to tolerate the diet or suffering significant side-effects were free to withdraw at any time. Ethics approval was obtained from the Flinders Clinical Research Ethics Committee.

Patients attended the hospital for a detailed medical history. Anthropometric measurements were taken (height, weight, waist and hip circumference) and fasting blood collected for monitoring of possible disturbances in electrolytes and liver function tests. Patients then underwent magnetic resonance

(MR) studies to determine liver size and fat content before commencing the VLCD.

## Optifast® VLCD

Patients were placed on Optifast® VLCD (Novartis Consumer Health Australasia Pty, Ltd) for a period of 6 weeks. Optifast® VLCD is a total diet replacement formulated to allow medically at-risk patients to rapidly and safely lose weight. Subjects were provided with 3 sachets/day of Optifast® meal replacement as well as information on other permitted low calorie foodstuffs to provide a total energy intake of between 450 and 800 kcal/day. Optifast® VLCD contains the recommended daily intake levels for vitamins and minerals. The low carbohydrate and fat content encourage a shift to fat breakdown and ketosis and the high protein content prevents the severe negative nitrogen balance associated with starvation and preserves lean body mass.<sup>17,18</sup>

## Patient Monitoring

Following initial MR studies and commencement of the diet, patients attended the hospital outpatient clinic every 2 weeks for monitoring of their weight and blood pressure. Any adverse effects of the diet were noted and issues with compliance were discussed.

At 6 weeks, the initial anthropometrical measurements, blood tests and MR studies were repeated.

## Measurement of Liver Size and Fat Content

### MRI Technique

A series of 10-mm gradient echo T1-weighted (TE 4.6 msec, TR 550 msec) trans-axial abdominal scans encompassing the entire liver were acquired in a single breath-hold using a 1.5T magnet (Philips Intera Master, Best, The Netherlands).

For spectroscopy studies, a Philips C3 circular surface coil was placed laterally over the subjects' right upper abdominal quadrant. Images were transferred to a local workstation for liver volumetric analysis.

### Liver Volume

Using Philips EasyVision software, the liver margins on each image were manually outlined and the total volume of the liver calculated by multiplying the measured surface area of each slice by the slice thickness and summing the volume of each slice.

### <sup>1</sup>H-NMR Spectroscopy

A 20x20x20 mm voxel was identified within the liver parenchyma using a single axial abdominal image. <sup>1</sup>H-NMR spectra were acquired using a point resolution spectroscopy sequence with (TE 31 msec, TR 3000 msec, 80 measurements) and without (TE 31 msec, TR 3000 msec, 32 measurements) water suppression.

The quantity of intrahepatocellular lipid (IHCL) in the liver voxel is represented by the area under the relevant peak in a Fourier-transformed free induction decay. This area is calculated by applying Lorentzian curve fitting and by the AMARES non-linear least squares algorithm. The results are expressed as a ratio of the area under the IHCL peak in the water suppressed sequence to that of the sum of the areas under the IHCL and water peaks derived from similar analysis of data from the unsuppressed sequence.

### Operative Access

The surgeons made a subjective assessment of ease of access to the gastro-esophageal junction and ability to adequately retract the left lobe of the liver. An objective measure was not taken.

### Statistical Analysis

Analysis was performed using SPSS V. 12 statistical software. Data are expressed as median and interquartile range. Changes between paired variables were assessed using the Wilcoxon Signed Rank test. After subdivision of the cohort according to the presence of liver steatosis (>0.05 AU), changes in liver volume and fat content were compared using the Mann-Whitney-U test. The relation between liver volume and liver fat was assessed

using Spearman's correlation coefficient. A *P*-value <0.05 was assumed to be statistically significant.

### Results

Twenty-three patients were eligible for enrollment into the study. Two patients were excluded, as they were unable to enter the MRI scanner due to excessive size. Of the 21 patients who started the Optifast diet, three patients withdrew after being unable to tolerate the diet. Eighteen patients (one male, 17 females, median age 50 [34-57] years) completed the 6-week study.

All patients who completed the study lost weight in the 6-week study period. Median excess weight loss was 15.1 [9.6-21.1] %. There were wide variations in the measurements of both liver volume and fat content at baseline in our study group (Table 1). Liver fat content in 61% of subjects (n=11) was >0.05 AU, indicative of fatty liver.<sup>19</sup> Significant reductions in liver volume and fat content occurred in the group as a whole at the end of the study period (Table 1). The relative reduction in liver fat and volume in those with liver steatosis was 72.5% (*P*=0.005) and 16.3% (*P*=0.005), respectively. The relative reduction in liver fat and volume in those without liver steatosis (n=7) was 0% (NS) and 9.4% (*P*=0.018), respectively. There was a significant difference in the absolute (*P*=0.001) but not relative (*P*=0.064) change in liver fat between subjects with and without liver steatosis. There was no significant difference in the change in liver volume between subjects with and without liver steatosis.

**Table 1. Baseline and changes in measures of adiposity before and after 6 weeks of Optifast® very low calorie diet**

	Baseline Measurements	After 6 Weeks Optifast®	<i>P</i>
Body weight (kg)	119.7 (111.9-131.3)	110.6 (98.0-124.5)	<0.001
Body mass index (kg/m <sup>2</sup> )	44 (40-51)	40 (36-47)	<0.001
Excess body weight (kg)	57.1 (52.2-70.3)	49.7 (36.6-63.6)	<0.001
Waist-to-hip ratio	0.85 (0.78-0.93)	0.86 (0.77-0.90)	0.015
Liver volume (ml)	2199 (1894 – 2548)	1934 (1635-2120)	<0.001
Liver fat (AU)	0.07 (0.03 – 0.26)	0.03 (0.01-0.14)	0.016

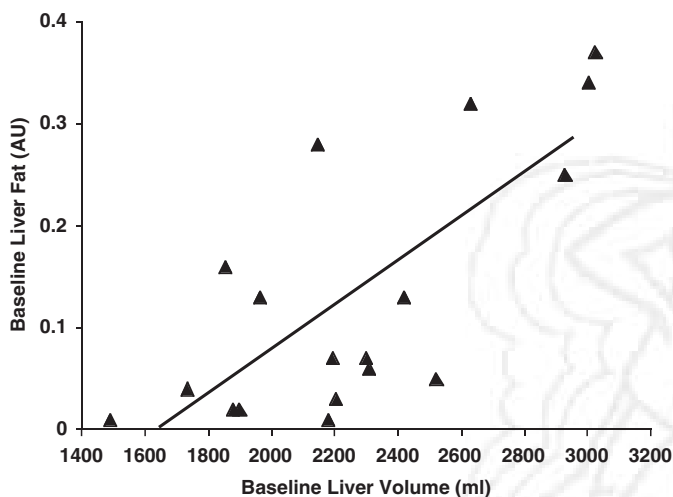
Data expressed as median (interquartile range)

### Association between Liver Size and Fat Content

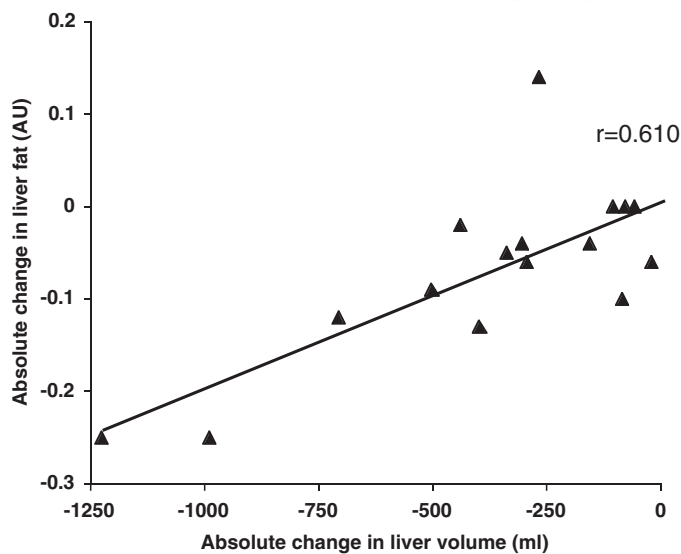
Regression analysis showed significant correlations between baseline liver volume and liver fat content ( $r=0.633$ ,  $P=0.005$ ; Figure 1) and between change in liver volume and liver fat content ( $r=0.610$ ,  $P=0.012$ ; Figure 2).

### Operative Access

Evaluation by the surgeon of ease of access to the gastro-esophageal junction was made subjectively and in all patients access was thought to be good with relatively easy retraction of a soft liver.



**Figure 1.** Relation between liver fat and liver size prior to commencement of Optifast® very low calorie diet ( $r=0.633$ ,  $P=0.005$ ).



**Figure 2.** Relation between changes in liver fat and size following 6 weeks Optifast® very low calorie diet ( $r=0.610$ ,  $P=0.012$ ).

## Discussion

Using the techniques of MRI and  $^1\text{H-NMR}$  spectroscopy, this study has clearly demonstrated that a large proportion of excess liver size in obesity is attributable to liver fat content and that by undergoing a 6-week period of Optifast® VLCD, a reduction in both the liver size and liver fat content occurs. The correlation between the changes in liver volume and liver fat suggests that the reduction in volume is related to loss of liver fat. It is possible that in addition to loss of liver fat, some of the volume loss may be related to a decrease in liver glycogen stores because liver volume decreased by about 10% in those obese patients who did not have hepatic steatosis prior to the VLCD. However, the study design did not permit measurement of liver glycogen stores.

In a previous study,<sup>14</sup> changes in liver volume were noted after a 2-week period of Optifast® VLCD. There was no correlation with total fat loss as estimated by a Tanita Body Analyzer. While the accuracy of this method needs to be defined, conclusions regarding liver fat content were not possible by the design of the study. In contrast, our study used a well described validated technique<sup>19,20</sup> for measuring liver fat content, and this technique has shown that the liver volume changes can be largely ascribed to loss of liver fat.

Whether the change in liver volume and liver fat contributed to improved operative access was not formally assessed by this study. It was the surgeon's subjective assessment that access to the gastro-esophageal junction was adequate and that the left lobe of the liver could be retracted without damage to it.

The optimal time for preoperative VLCD has not been defined. In a previous study,<sup>14</sup> only 2 weeks were used and the surgeons subjectively concluded that this period improved access. However, similar to our study, there was no formal measure to evaluate this effect. Our selection of 6 weeks preoperative VLCD was based on our view that we wanted to achieve as large an effect as possible, taking into account patients' ability to remain compliant with the dietary regimen. In retrospect, we believe the length of time chosen was sufficient and tolerated by most of the patients.

In summary, significant related reductions in liver volume and fat content occurred in our patients fol-

lowing 6-weeks of Optifast® VLCD. We hypothesize that it is this reduction in liver volume that improves operability in patients undergoing laparoscopic bariatric surgery.

Optifast® VLCD used in this study was donated by Novartis Consumer Health Australasia, Pty. Ltd.

## References

- Blackburn GL, Mun EC. Effects of weight loss surgeries on liver disease. Semin Liver Dis 2004; 24: 371-9.
- Clouston AD, Powell EE. Nonalcoholic fatty liver disease: is all the fat bad? Intern Med J 2004; 34: 187-91.
- Wolf AM, Busch B, Kuhlmann HW et al. Histological changes in the liver of morbidly obese patients: correlation with metabolic parameters. Obes Surg 2005; 15: 228-37.
- Cuadrado A, Orive A, Garcia-Suarez C et al. Non-alcoholic steatohepatitis (NASH) and hepatocellular carcinoma. Obes Surg 2005; 15: 442-6.
- Angulo P. Nonalcoholic fatty liver disease. N Engl J Med 2002; 346: 1221-31.
- Dixon JB, Bhathal PS, O'Brien PE. Nonalcoholic fatty liver disease: predictors of nonalcoholic steatohepatitis and liver fibrosis in the severely obese. Gastroenterology 2001; 121: 91-100.
- Nomura F, Ohnishi K, Ochiai T et al. Obesity-related nonalcoholic fatty liver: CT features and follow-up studies after low-calorie diet. Radiology 1987; 162: 845-7.
- Tiikkainen M, Bergholm R, Vehkavaara S et al. Effects of identical weight loss on body composition and features of insulin resistance in obese women with high and low liver fat content. Diabetes 2003; 52: 701-7.
- Andersen T, Gluud C, Christoffersen P. The effect of very low calorie diet on liver morphology. Int J Obes 1989; 13 (Suppl 2): 153-4.
- Stratopoulos C, Papakonstantinou A, Terzis I et al. Changes in liver histology accompanying massive weight loss after gastroplasty for morbid obesity. Obes Surg 2005; 15: 1154-60.
- Dixon JB, Bhathal PS, Hughes NR et al. Nonalcoholic fatty liver disease: Improvement in liver histological analysis with weight loss. Hepatology 2004; 39: 1647-54.
- Mottin CC, Moretto M, Padoin AV et al. Histological behaviour of hepatic steatosis in morbidly obese patients after weight loss induced by bariatric surgery. Obes Surg 2005; 15: 788-93.
- Busetto L, Tregnaighi A, De Marchi F et al. Liver volume and visceral obesity in women with hepatic steatosis undergoing gastric banding. Obes Res 2002; 10: 408-11.
- Fris RJ. Preoperative low energy diet diminishes liver size. Obes Surg 2004; 14: 1165-70.
- Buchwald H, Williams SE. Bariatric surgery Worldwide 2003. Obes Surg 2004; 14: 1157-64.
- Alvarado R, Alami RS, Hsu G et al. The impact of preoperative weight loss in patients undergoing laparoscopic Roux-en-Y gastric bypass. Obes Surg 2005; 15: 1282-6.
- Tsai AG, Wadden TA. Systematic review: An evaluation of major commercial weight loss programs in the United States. Ann Intern Med 2005; 142: 56-66.
- Saris WHM. Very-Low-calorie diets and sustained weight loss. Obes Res 2001; 9 (Suppl 4): 295S-301S.
- Szczepaniak LS, Nurenberg P, Leonard D et al. Magnetic resonance spectroscopy to measure hepatic triglyceride content: prevalence of hepatic steatosis in the general population. Am J Physiol Endocrinol Metab 2005; 288: E462-8.
- Thomsen C, Becker U, Winkler K et al. Quantification of liver fat using magnetic resonance spectroscopy. Magn Reson Imaging 1994; 12: 487-95.

(Received February 8, 2006; accepted March 15, 2006)